PATIENT CARE THEORY 2

UNIT 12, PART 2: Abdominal Assessment

Marilyn Niffin BSc, ACP
Professor Georgian College
Winter 2020, 2021, 2024

Learning outcomes

At the conclusion of this presentation, the learner will be able to:

- describe the basic anatomy and physiology of the abdominal organs
- Discuss the anatomy and physiology of the gastrointestinal system and its relation to acute pain
- list and locate the quadrants used to simplify the abdominal assessment
- describe visceral, somatic and referred pain
- list and explain all the elements of an OPQRST assessment and provide examples of these elements for the different organs of the abdomen
- describe associated signs and symptoms and provide examples of where their existence provides supportive evidence to the field diagnosis
- list and describe important elements in the history
- describe the causes of abdominal pain and list the signs and symptoms that would support the field diagnosis

Introduction

- why assess the abdomen in the prehospital setting?
- High percentage of patients p[resent to ER with abdominal pain (10-25%)
- 15-30% of patients with an acute abdomen will require a surgical procedure
- Are usually the result of underlying pathological processes
  - Often self-induced risk factors precipitate or complicate these conditions (excessive alcohol consumption, smoking, stress, ingestion of caustic substances, poor diet/bowel habits etc.)

How do we assess Abdo Pain?

- Using our O-P-Q-R-S-T we can usually differentiate between acute and chronic conditions
- Assessments also help determine potential severity

General Pathophysiology

- Hallmark symptom of acute abdominal emergency is pain
- Types of pain
  - Visceral
  - Somatic
  - Referred

Neuroanatomy of abdominal pain

Visceral pain

- stimulated by distension, inflammation and/or ischemia
- stretch receptors in the walls and capsules of hollow organs
- ***dull, achy***, cramping or gassy pain
- ***Poorly localized***
- epigastrium , periumbilical or suprapubic area
- ***comes and goes (colicky)***
- presents with nausea and vomiting, diaphoresis and tachycardia

Neuroanatomy of abdominal pain

Somatic/ Parietal

- ***constant and localized***
- Skin, skeletal muscle, joints/ parietal (lining of the abdominal cavity)
- Divided into superficial and deep
- knife like with increased pain on movement
- presents with guarding and lying on side or back with legs up
- usually caused from bacterial or chemical irritation of nerves

Neuroanatomy of abdominal pain

Referred

- Pain located nowhere near where the affected organ
- Due to neurons that share the same pathway or from where the organ was formed during embryonic development
  - e.g. ruptured spleen causes left shoulder pain (Kehr's sign*).
  - Back/between the shoulder blades pain is also a common occurrence with abdominal pain – classic in AAA

* "blood or other irritants in the peritoneal cavity when a person is lying down and the legs are elevated. **Kehr's sign** in the left shoulder is considered a classic symptom of a ruptured spleen."

Anatomy

- Gastrointestinal system involves the esophagus,stomach, small and large intestines
- They work with the pancreas, liver and gallbladder to convert nutrients from food into energy. Waste is then excreted

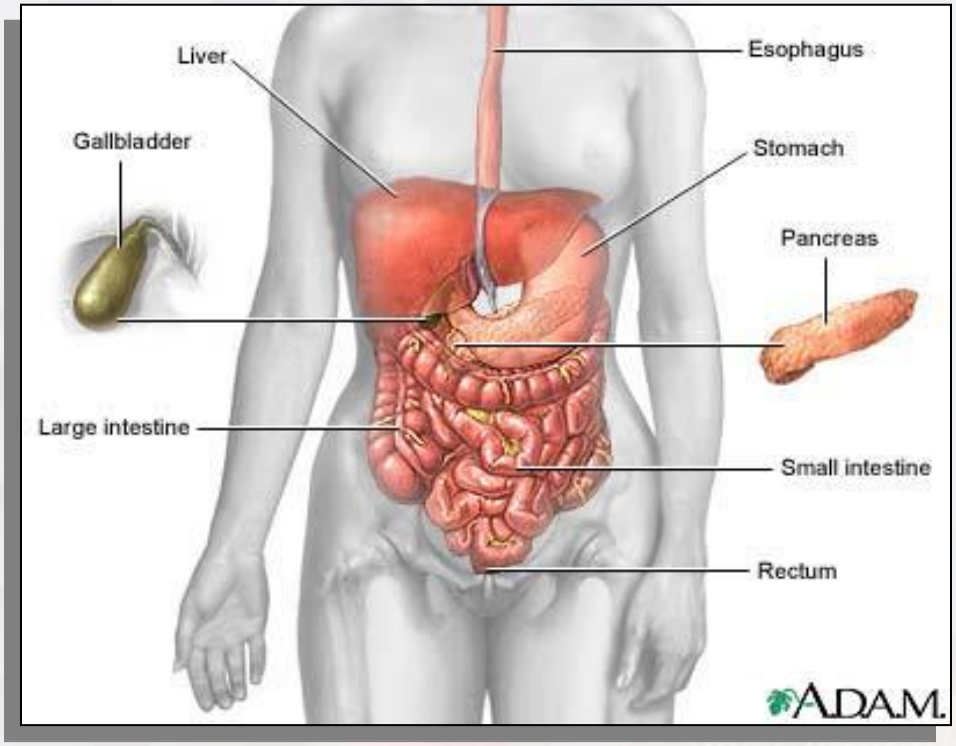

Anatomy

- The upper GI tract includes:
  - Mouth
  - Esophagus
  - Stomach
  - Duodenum
- Lower GI tract
  - Small intestine (duodenum, jejunum, ileum)
  - Large Intestine (Cecum, Colon – ascending, transverse, descending, sigmoid)
  - Rectum
  - Anus

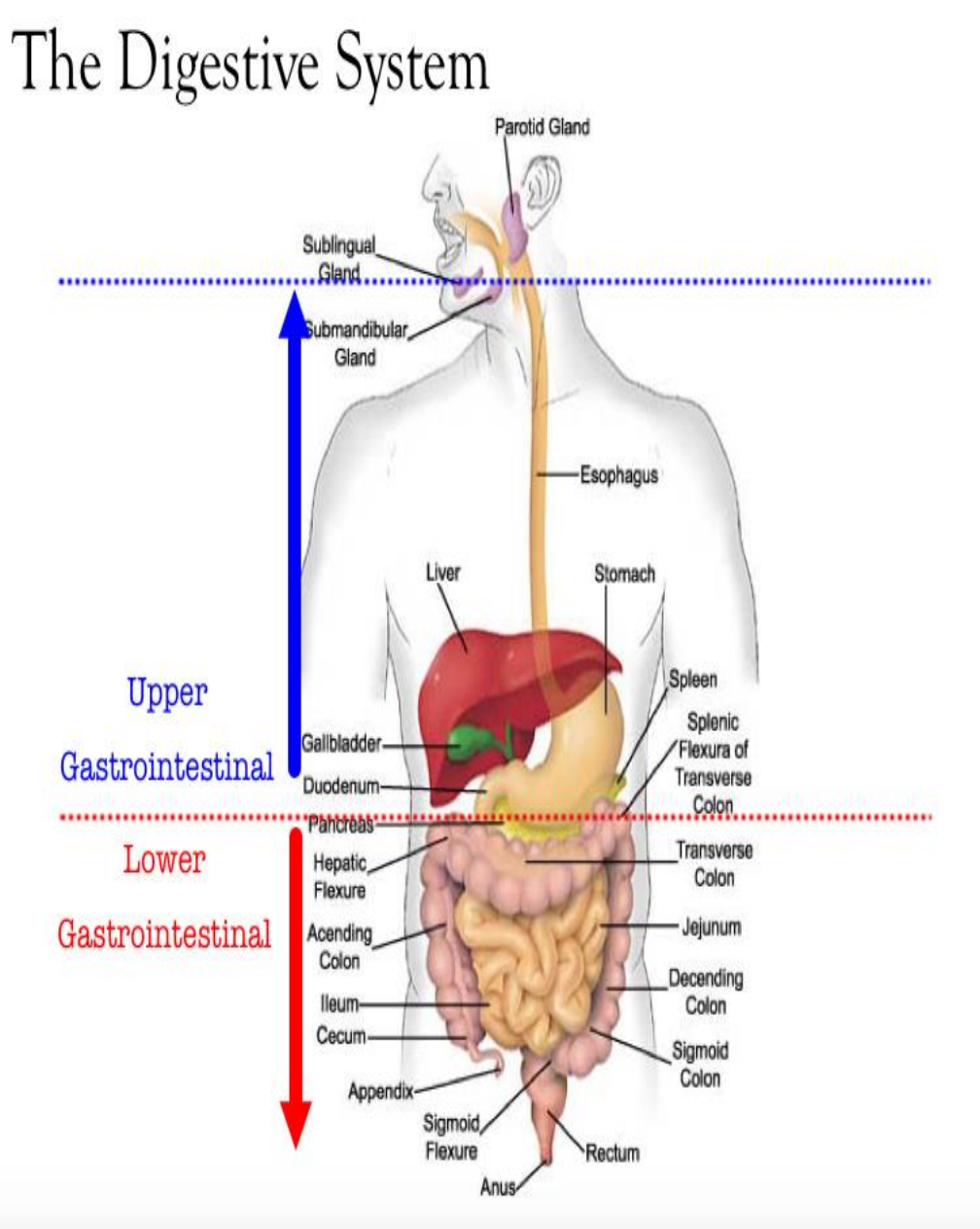

Anatomy - 4 Quadrant System

Right Upper Quadrant (RUQ) • diaphragm • liver • gallbladder • kidney • ascending colon • small intestine	**Left Upper Quadrant (LUQ)** • spleen • pancreas • stomach • kidney • descending colon • small intestine
Right Lower Quadrant (RLQ) • appendix • large ascending colon • ovary • uterus • bladder • small intestine	**Left Lower Quadrant (LLQ)** • descending colon • Sigmoid colon • ovary • uterus • bladder • small intestine

Anatomy - 9 Quadrant System

Right Hypochondriac	Epigastric	Left Hypochondriac
Right Lumbar	Umbilical	Left Lumbar
Right Iliac	Hypogastric (suprapubic)	Left Iliac

See graphic on next slide

Anatomy - 9 Quadrant System

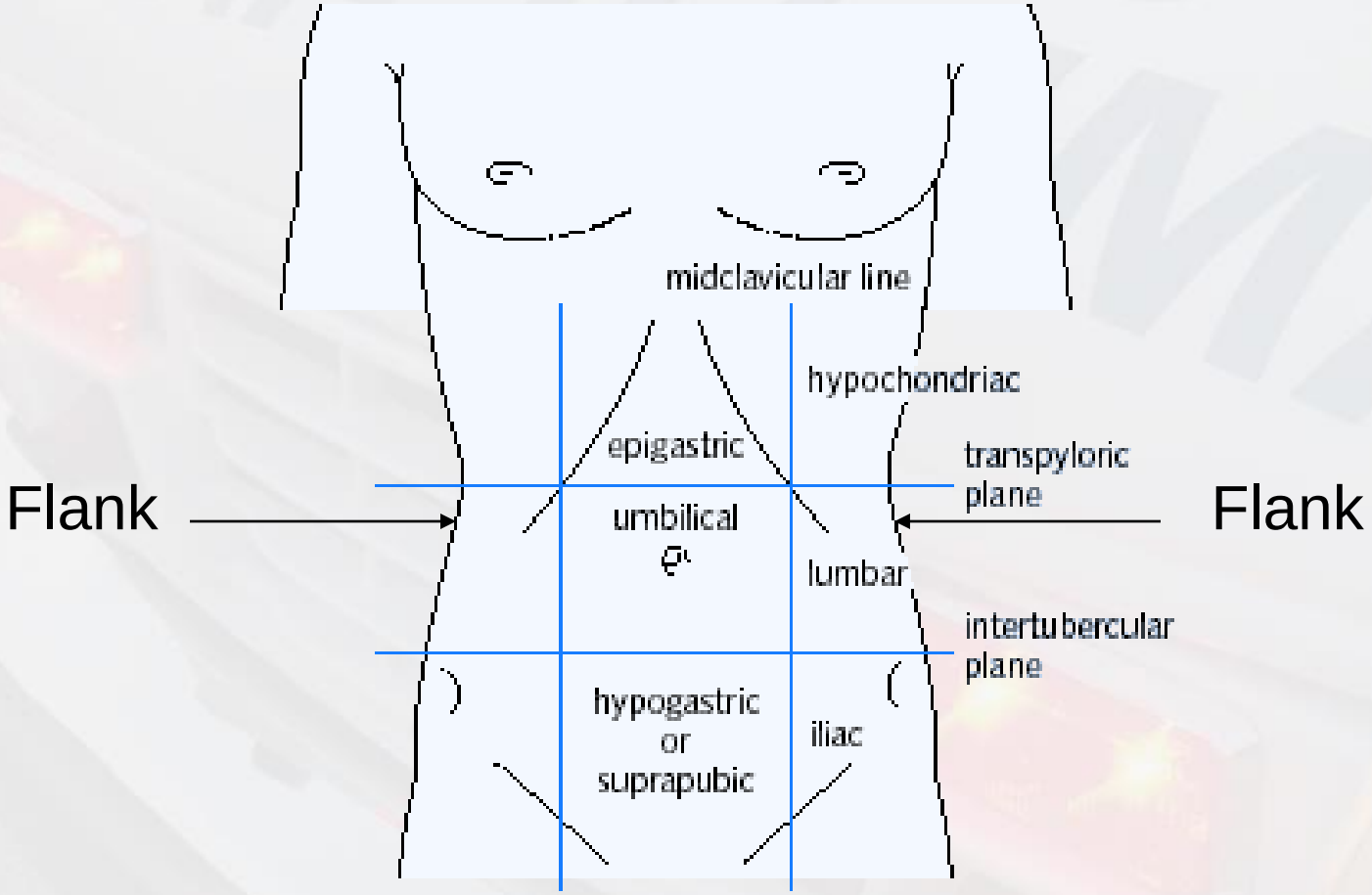

Anatomy of Abd vessels

- The descending aorta runs through the abdomen
- The hepatic artery branches off and supplies the liver
- The mesenteric artery branches off and supplies the stomach and intestines

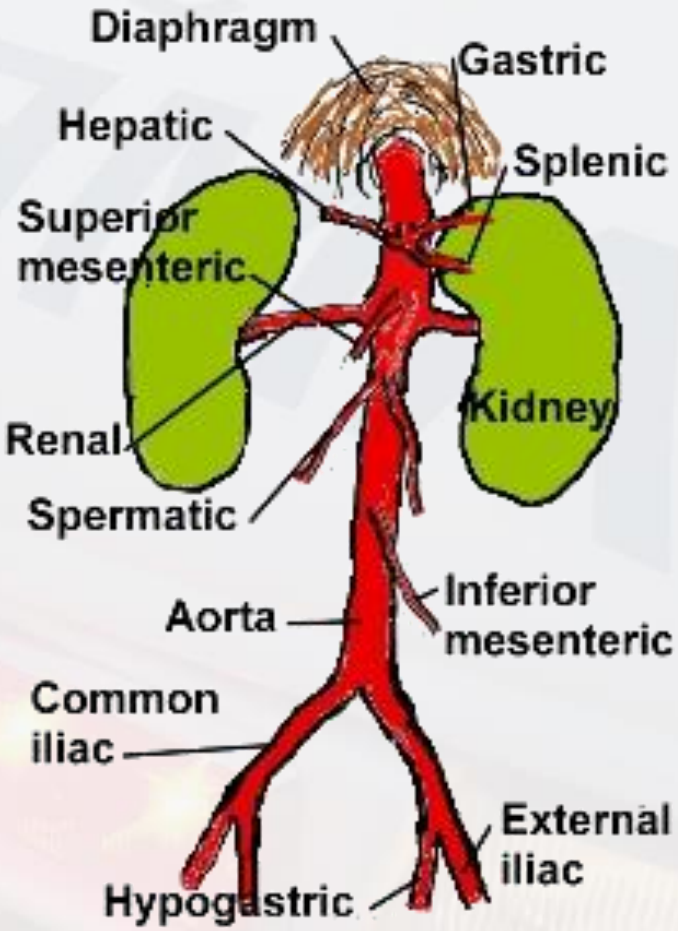

Assessment of Abd pain
O-P-Q-R-S-T

- **ONSET**
- When did it start? What were you doing?
- ***Sudden***/rapid onset of ***severe*** pain is more consistent with a vascular catastrophe, passage of a ureteral or gallbladder stone, torsion of the testes or ovaries, rupture of a hollow viscus, ovarian cyst, or ectopic pregnancy
- slower onset is more typical of an inflammatory process such as appendicitis or cholecystitis or the blockage of a hollow organ

Assessment of Abd pain
O-P-Q-R-S-T

Provokes / palliates

- What makes it worse? What makes it better?
- pain provoked/aggravated by movement, such as hitting bumps on the road or walking is typical of somatic peritoneal pain – e.g. pancreatitis
- eating often relieves ulcer related pain
- eating exacerbates cholecystitis & biliary colic
- pancreatitis is palliated by curling up in a fetal position
- frequent movement or writhing - typical of renal colic

Assessment of Abd pain
O-P-Q-R-S-T

Quality

- What does it feel like?
- dull, achy or crampy is more likely to be visceral (Dull steadily increasing pain could be a bowel obstruction)
- sharp, stabbing pain is more likely to be somatic or peritoneal (sharp pain in the flank area likely renal colic)
- severe tearing pain is classic of dissecting abdominal aortic aneurysm or the rupture of an organ (localized)

Assessment of Abd pain
O-P-Q-R-S-T

Region / radiation

- Where is it? Does it go anywhere?
- location of pain can vary with time
- periumbilical pain that migrates to the right lower quadrant is classic of appendicitis
- epigastric pain localizing to the right upper quadrant for several hours is typical of cholecystitis

Assessment of Abd pain
O-P-Q-R-S-T

Severity

- How bad is the pain?
- A 10 scale doesn't separate the benign from the life-threatening
- Sets a baseline to gauge response to Tx
- *pain that increases in severity over time suggests a surgical condition*
- severe epigastric or mid abdominal pain out of proportion to physical findings is classic for mesenteric ischemia or pancreatitis

Assessment of Abd pain
O-P-Q-R-S-T

Timing

- Is it constant? Does it come and go?
- crampy pain that comes in waves is generally associated with obstruction of a viscus
- constant pain has a worse diagnostic outcome
- *Consistent pain lasting more than 6 hours should be transported*

Three critical characteristics

Sudden* – *Severe* - *Constant

Associated signs & symptoms (and pertinent negatives)

Nausea & vomiting (N/V)

- N/V = visceral disorder
  - Attempt to determine amount, colour, consistency of emesis; hematemesis? (coffee ground appearance suggests GI bleed)
- excessive vomiting = query bowel obstruction or pancreatitis
- lack of vomiting - common in uterine or ovarian disorders
- ***pain present before vomiting*** - query surgical candidate
- vomiting preceding abdominal pain = gastroenteritis or other non-surgical condition

Associated signs & symptoms

Urgency to defecate

may suggest…

- intra-abdominal bleeding
- inflammation/irritation in the rectosigmoid area
- ectopic pregnancy
- abdominal aortic aneurysm (AAA)
- retroperitoneal hematoma
- omental vessel hemorrhage

Associated signs & symptoms

Anorexia

- intra-abdominal inflammation
- common in appendicitis

Associated signs & symptoms

Change in bowel habits

- diarrhea with vomiting is almost always associated with gastroenteritis
- diarrhea may occur with pancreatitis, diverticulitis and occasionally appendicitis
- bloody stool indicates GI bleed
  - Black tarry stool likely ulcer or upper GI tract issue
  - Bright red blood/clots in stool likely lower GI (diverticulitis, hemorrhoids)
- constipation or difficulty passing stool or gas may be due to an ileus or bowel obstruction

Associated signs & symptoms

- **Genitourinary symptoms**
- dysuria, urgency and frequency are suggestive of cystitis (UTI), salpingitis (Inflammation of the fallopian tubes), diverticulitis (pouch-like bulges or pockets [diverticula] in the wall of the intestine [mostly colon] which become infected) or appendicitis
- hematurea with pain suggests urinary tract infection (UTI), but can also indicate renal colic, prostatitis or cystitis

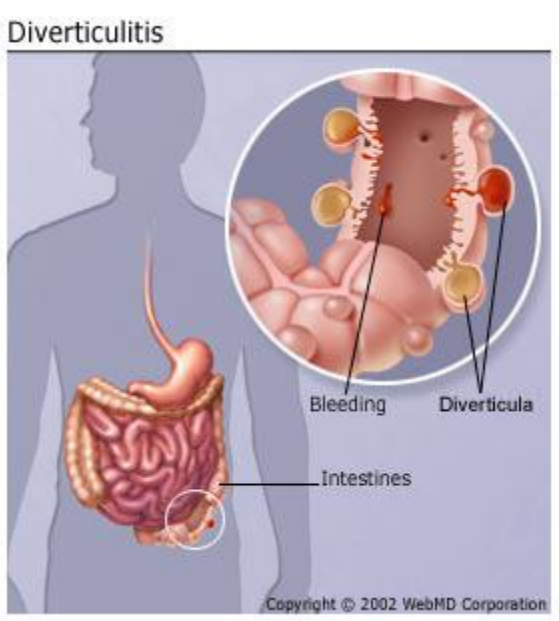

Associated signs & symptoms

muscle strain from coughing

Extra-abdominal symptoms

- myocardial infarction
- Pneumonia
- pulmonary embolus

} can present with abdominal pain

Fever

Pregnancy

Orthostatic vital signs

Dizziness

Pedal pulses

Associated Signs and Symptoms

early trimester pains more concerning, as late trmester pains are common from strain

- SAMPLE
  - any history of similar complaint?
  - are they pregnant, and which trimester are they in?
  - any history of hypertension, cardiac or respiratory disease?
  - Position of comfort?
  - have they eaten/drank anything different?
  - any excessive alcohol or drug use?

Relevant history

Past medical history

- prior abdominal surgery is a common cause of adhesions and can lead to bowel obstruction
- prior surgery may also help eliminate certain diagnosis – e.g. appendicitis, cholecystitis
- Diabetes, heart disease, lung disease, liver disease, hypertension, or renal disease increase the risk of abdominal disorders – e.g. HTN is associated with abdominal aortic aneurysm, atrial fibrillation is a common cause of emboli in the mesenteric vessels and can lead to infarction of parts of the GI tract and an ileus or bowel obstruction

Relevant history

Medication

- corticosteroids /immunosuppressants Opioids can cause constipation and bowel obstruction
- antibiotics may cause GI discomfort/diarrhea – *erythromycin and tetracycline
- laxatives, narcotics and psychotropic medication may alter GI motility –
- ASA and other NSAIDS can cause gastritis, peptic ulcer and GI bleeding

Complete Abdominal Assessment

- Inspection
- Palpation
- Percussion
- Auscultation

Becomes:

- I
- A
- P
- P

Always auscultate before palpating when doing an abdominal assessment – the palpation may alter the bowel motility and associated sounds

** *we generally do not use percussion as an assessment tool in the prehospital/uncontrolled environment*

Assessment of Abdominal Pain

- Ensure your patient is relaxed (as possible)
- Good lighting
- Comfortable and properly positioned
  - Lying supine with head supported and knees bent (can place a pillow or blanket under); this will help to relax to abdominal muscles
- Expose the abdomen
  - You want to be able to visualize from the costal margin to just above the symphysis pubis
- Ask you patient to point to where they feel the pain
- Make sure your hands are warm!

Inspection

- Distention can be an ominous sign (if abnormal for patient)
  - Air build up from bowel obstruction
  - Hemorrhage (abd can hold 4-6 L of fluid before visible girth changes)
- Look at the skin colour
  - Cullen's sign – ecchymosis in the periumbilical area
  - Grey-Turner's sign – ecchymosis of the flank
    - These are signs of intraabdominal Hemorrhage or fluid loss
- Look for any scars, bruising, redness, rashes, masses (pulsatile or otherwise), or other trauma, hernias or bulges, asymmetry, ascites

Auscultation

- Requires a quiet environment
- Listen carefully – beginning in the quadrant furthest from the affected area -> affected quadrant last
  - Normal bowel sounds include various pitches and gurgles q 5- 15 seconds
    - Continuous or more frequent indicate increased bowel motility (gas, diarrhea, early intestinal obstruction)
  - Absence of bowel sounds below affected area may indicate obstruction (greater than 2 minutes)

Palpation

- Similar to auscultation, palpate in reverse order working toward the affected painful area (palpated last)
- Monitor patients' facial expressions for pain and discomfort
- Place the patient flat with knees flexed to relax abdominal muscles
- Use broad gentle pressure
- Feel for guarding, muscle tension (or absence), masses, pulsations, tenderness
  - Pulsations – immediately stop palpating
- Assess for rebound tenderness –
  - press slowly and release quickly – pain on release indicates peritoneal inflammation (*having the patient cough can also determine peritoneal inflammation without causing the patient increased pain*)

Management of Abd Pain

BP may remain stable during dehydration, as cells will initially send fluid out to blood to compensate

- ECG, SpO_2, temperature
- Consider O_2 if…
  - SOB or dyspnea
  - Suspected blood loss with ↓ O_2 carrying capacity
  - Suspected Abd organ ischemic pain
  - Unexplained poor saturation
- Ketorolac is preferred for known renal colic
  - Otherwise follow the medical directive for analgesia
- IV for fluid resuscitation prn
- **Take <u>all</u> Abd pain seriously**
  - **If they look sick……they are!**
- Transport

QUESTIONS?